

Colposcopy report

08 March 2022

Dr. J. Martin*

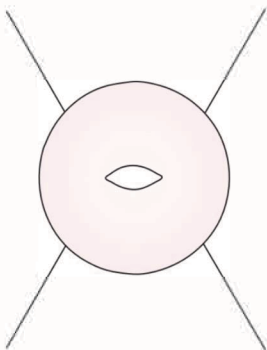
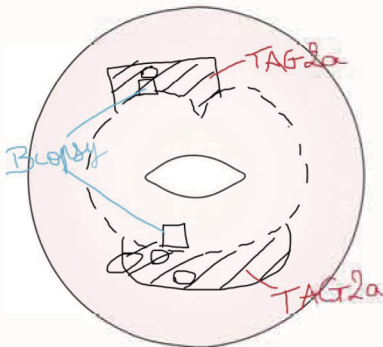
06.06.06.06.06

University diploma of colposcopy

 delmont
imaging

Laure Morel*

Born 04 December 1992



LMP: 28/05/2018

Gestivity: G0

Parity: P0

HPV vaccine: Yes

Tobacco use: No

Treatment: None

Liaison physician: Dr. Marie Dupont*

Indication: NO

Previous cytological or virological results: -

History of previous treatments: None

Previous histological results: -

Interpretable colposcopy: Yes

Grade: Normal (G0)

Transformation zone: TZ 1

Surface: Q3

Aspect of the glandular epithelium: Normal

Vagina aspect: Normal

Cervical biopsy: Performed

Location Cervical biopsy: 7o'clock, 11o'clock

Vaginal biopsy: Not performed

Location Vaginal biopsy: -

Endocervical curettage: Not performed

Biopsy result: (pending results)

Comments: -

Course of action and conclusions: Satisfying colposcopy.
TAG2a with surrounded glands orifices.
Biopsy results x2

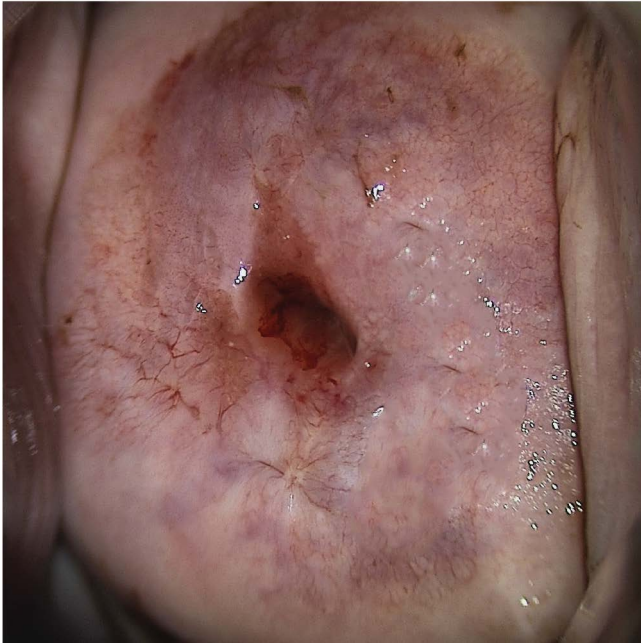

1/2

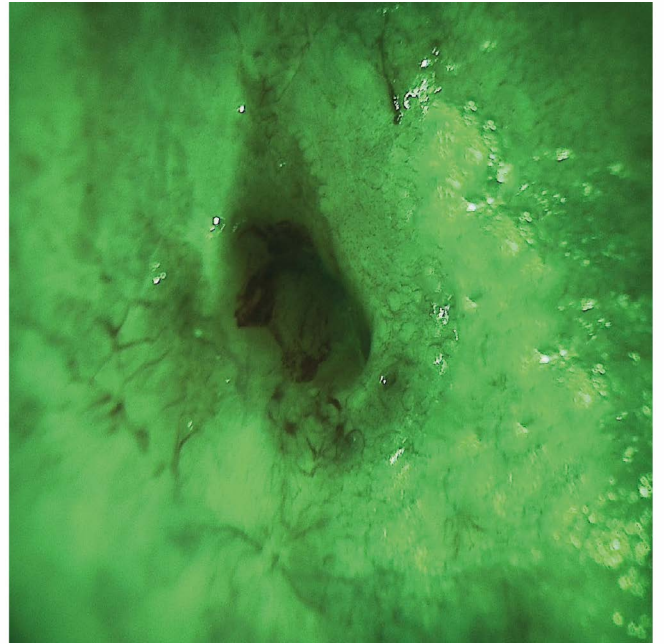
Colposcopy report

08 March 2022

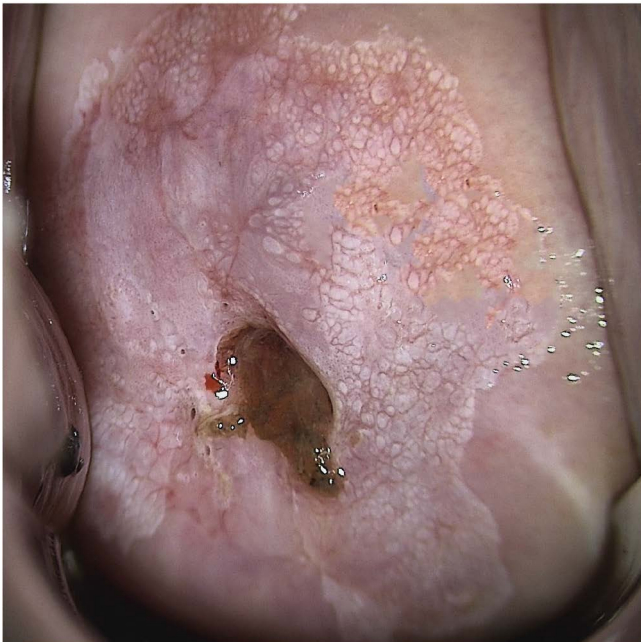Laure Morel*
Born 04 December 1992



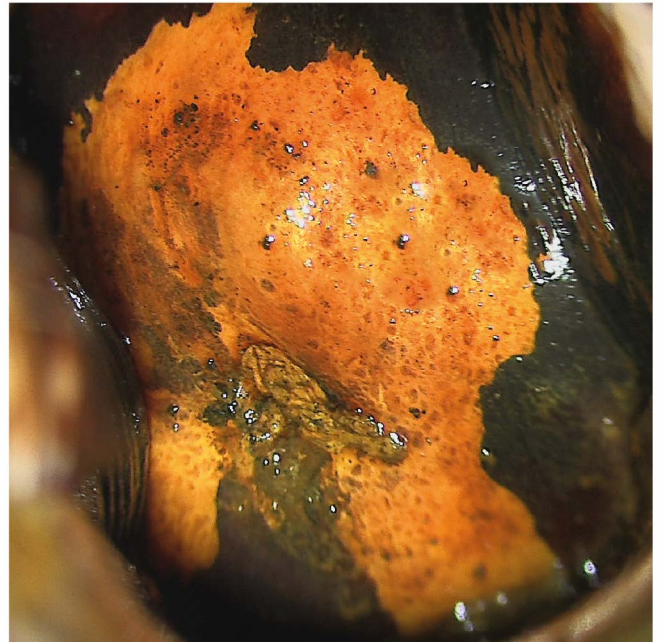
No treatment



With green filter



With acetic acid



With lugol