

Colposcopy report

08 March 2022

Dr. J. Martin*

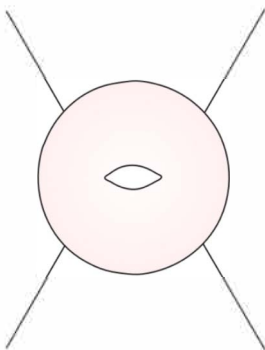
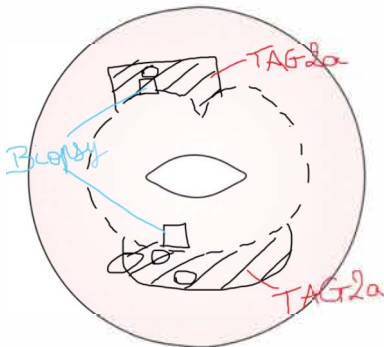
06.06.06.06.06

University diploma of colposcopy

 delmont
imaging

Laure Morel*

Born 04 December 1992



LMP: 28/05/2018

Gestivity: G0

Parity: P0

HPV vaccine: Yes

Tobacco use: No

Treatment: None

Liaison physician: Dr. Marie Dupont*

Indication: NO

Previous cytological or virological results: -

History of previous treatments: None

Previous histological results: -

Colposcopic aspect: TAG2a

Transformation zone: Totally well seen Type 1 TZ

Number of concerned quadrants: Q3

Location of major cervical lesions: Anterior lip 11o'clock, Posterior lip 7o'clock

Vagina aspect: Normal

Location of vaginal lesions: -

Biopsy: Performed

Biopsy location: 11o'clock ant lip, 7o'clock post lip

Endocervical curettage: Non-performed

Biopsy result: (waiting for results)

Comments: -

Course of action and conclusions: Satisfying colposcopy.

TAG2a with surrounded glands orifices.

Biopsy results x2



Colposcopy report

08 March 2022

Dr. J. Martin*

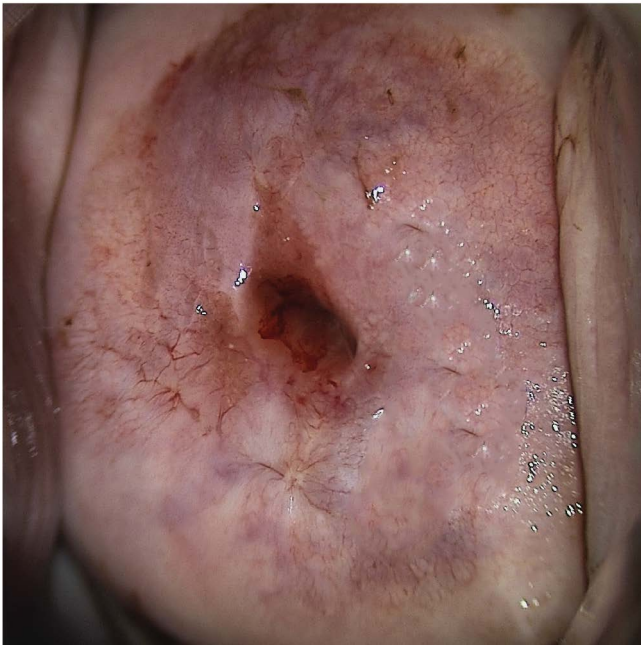
06.06.06.06.06

University diploma of colposcopy

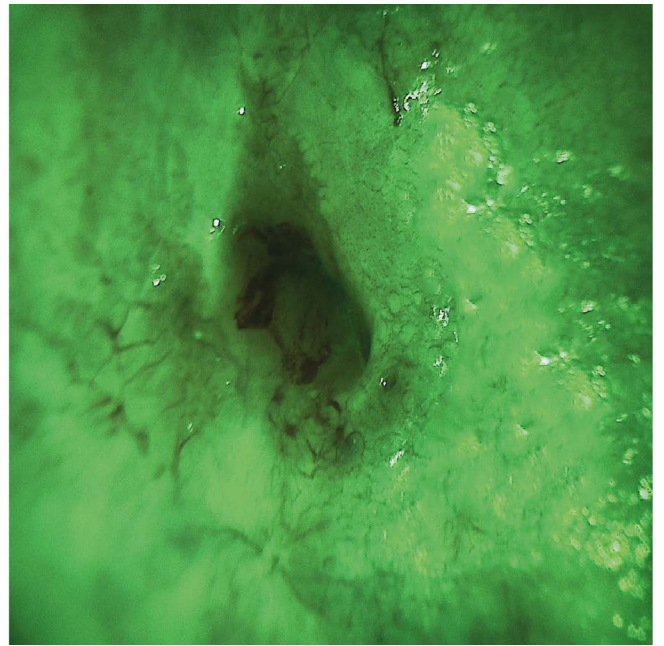


Laure Morel*

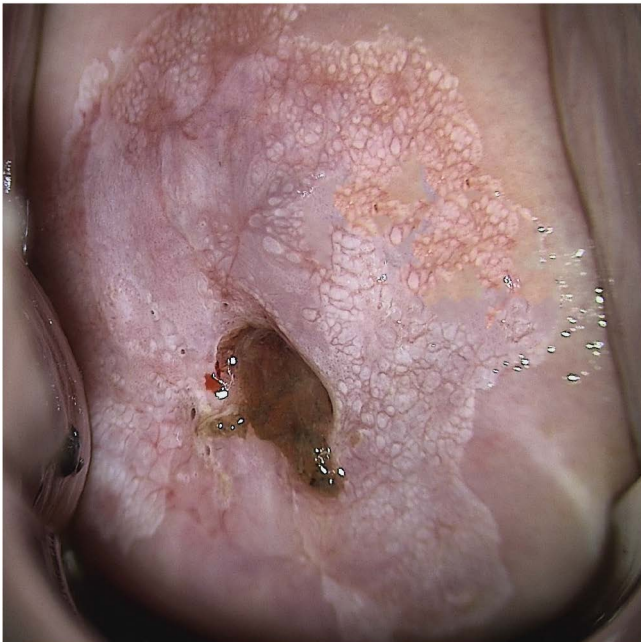Born 04 December 1992



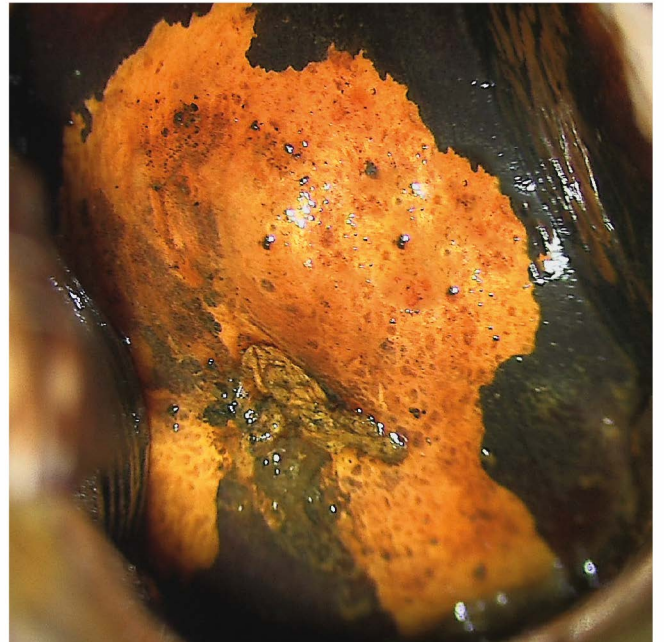
No treatment



With green filter



With acetic acid



With lugol